Journal of Community Hospital Internal Medicine Perspectives

Volume 14 | Issue 6 Article 5

2024

Evaluating the Cavitary Lung Lesions on CT Scan of COVID-19 Patients: A Retrospective Study

Golnaz Moradi
Department of Radiology, Sina Hospital, school of medicine, Tehran University of Medical Sciences

Safa Samadzadeh Etehadi
Tehran University of Medical Sciences, Tehran, Iran

Seyed Hamid Mousavi
Department of Urology, Tehran University of Medical Sciences, Tehran, Iran.

Rayeheh Mohammadi
Department of Radiology, Sina Hospital, school of medicine, Tehran University of Medical Sciences, b_sh2110@yahoo.com

Follow this and additional works at: https://scholarlycommons.gbmc.org/jchimp

Recommended Citation

Moradi, Golnaz; Etehadi, Safa Samadzadeh; Mousavi, Seyed Hamid; and Mohammadi, Rayeheh (2024) "Evaluating the Cavitary Lung Lesions on CT Scan of COVID-19 Patients: A Retrospective Study," *Journal of Community Hospital Internal Medicine Perspectives*: Vol. 14: Iss. 6, Article 5.
DOI: 10.55729/2000-9666.1411
Available at: https://scholarlycommons.gbmc.org/jchimp/vol14/iss6/5

This Research Article is brought to you for free and open access by the Journal at GBMC Healthcare Scholarly Commons. It has been accepted for inclusion in Journal of Community Hospital Internal Medicine Perspectives by an authorized editor of GBMC Healthcare Scholarly Commons. For more information, please contact GBMCcommons@gbmc.org.

RESEARCH ARTICLE

Evaluating the Cavitary Lung Lesions on CT Scan of COVID-19 Patients: A Retrospective Study

Golnaz Moradi [a], Safa S. Etehadi [b], Seyed H. Mousavi [c], Rayeheh Mohammadi [a,*]

[a] Department of Radiology, Sina Hospital, School of Medicine, Tehran University of Medical Sciences, Tehran, Iran
[b] Tehran University of Medical Sciences, Tehran, Iran
[c] Department of Urology, Tehran University of Medical Sciences, Tehran, Iran

Abstract

Background: **It has been shown that cavitary lesions on CT scans of patients with COVID-19 may be related to their clinical symptoms and mortality rate.**

Materials and methods: **The study population included patients diagnosed with COVID-19 based on RT-PCR results from throat samples or typical clinical and chest CT scan findings who were hospitalized at Sina Hospital in Tehran in 2020 and underwent chest CT scans. Chest CT scans were examined for the severity of pulmonary opacities and the presence, number, size, wall thickness, and distribution of cavitary lung lesions.**

Results: **Oxygen saturation was lower in patients with cavitary lesions in the initial state and after treatment than those without cavitation, and a statistically significant relationship was observed ($p < 0.05$). In terms of gender, a significant correlation was observed, and the prevalence of cavitary lesions was higher in men ($p < 0.05$). Also, the in-hospital mortality rate was higher in patients with cavitary lesions ($p < 0.05$).**

Conclusion: **Based on our results, the presence of cavitary lung lesions in COVID-19 patients is related to the mortality rate, severity of pulmonary involvement, and patients' gender.**

Keywords: COVID-19, Cavitary lesion, CT scan

1. Introduction

Coronavirus disease 2019 (COVID-19) is a viral infection first identified in Wuhan, China, in 2019. At first, the clinical symptoms and pathogenesis of the virus were obscure.[1-3] Gradually, as COVID-19 spread, the virus emerged as a pandemic. COVID-19 infection causes inflammation, coagulation reactions, and death in patients, although the disorder primarily involves the respiratory tract.[4-6]

COVID-19 affects the respiratory system and causes disturbances in oxygen saturation.[3,7] Diagnosis is primarily based on clinical findings and molecular analysis, such as polymerase chain reaction (PCR) testing from throat swabs. However, a chest CT scan is considered a diagnostic test during the COVID-19 pandemic.[8-11] It has been determined that chest CT scans can be important in identifying high-risk people.

Cavitary lesions are pathologic processes that occur secondary to infection and conditions such as malignancies and rheumatologic diseases. A CT scan visualizes it as a gas-filled space with a thick wall.[12,13]

It has been shown that cavitary lesions on CT scans of patients with COVID-19 are related to their clinical presentations and laboratory findings.[14,15] Also, it has been shown that cavitary lesions on CT scans can be associated with complications such as thrombosis and thromboembolism.[16-19] Hitherto, few studies have evaluated the correlation between cavitary lesions in COVID-19 patients and the clinical symptoms and the mortality rate. In this study, we evaluated the presence and characteristics of cavitary lesions in patients with COVID-19 and

Received 1 April 2024; revised 12 August 2024; accepted 29 August 2024.
Available online 2 November 2024

* Corresponding author.
E-mail addresses: golnazz.moradi@gmail.com (G. Moradi), Safase940@gmail.com (S.S. Etehadi), Dr.ha.mousavi@gmail.com (S.H. Mousavi), rayehe.sm@gmail.com (R. Mohammadi).

https://doi.org/10.55729/2000-9666.1411
2000-9666/© 2024 Greater Baltimore Medical Center. This is an open access article under the CC BY-NC license (http://creativecommons.org/licenses/by-nc/4.0/).

investigated its relationship with patients' clinical presentations and prognosis.

2. Materials and methods

2.1. Study population

This retrospective cross-sectional study was conducted in 2020 at Sina Hospital in Tehran, Iran. Sina Hospital is a referral university-affiliated hospital and one of the major COVID-19 centers.

The inclusion criteria comprised all hospitalized individuals diagnosed with COVID-19 who underwent chest CT scans. The diagnosis of COVID-19 was based on positive real-time polymerase chain reaction (RT-PCR) results from throat swab samples or typical clinical symptoms and characteristics COVID-related changes on chest CT scans. COVID-related findings on CT scans include bilateral or peripheral ground-glass opacity or consolidation.

Exclusion criteria included individuals with cavitary lung lesions attributed to other pathologies such as malignancy and collagen vascular disease. Demographic, clinical, and laboratory data were extracted from medical records.

2.2. CT scan acquisition and image analysis

This study employed a 16-slice multi-detector Philips Ingenuity Flex CT scanner to acquire high-definition, thin-layer images of the chest. Scan settings included a slice thickness of 1.5 mm, a tube voltage of 120 kVp for standard-sized patients and 140 kVp for obese patients, and an average tube current of 70 mAs. Rotation time was set at 0.5 s with a pitch value of 1.438. Collimation was configured at 16×1.5 mm. The field of view (FOV) was adjusted for each patient to capture the entire area of interest. Dose Right technology was utilized to minimize radiation exposure. Two radiologists with over eight years of specialized experience using the MarcoPACS system assessed all images. The images were evaluated for cavitary lesions, their number, size, wall thickness, and distribution. The severity of lung involvement was reviewed using the semi-quantitative scoring system.[20] Each lobe was visually scored from zero to five (no involvement scored 0, <5% involvement scored 1, 5–25% scored 2, 26–49% scored 3, 50–75% scored 4, and >75% scored 5). The final score was the sum of all five lobes ranging from zero to 25. The presence of pneumothorax was documented.

2.3. Statistical analysis

The data were analyzed using SPSS version 26. Descriptive statistics were used to report quantitative variables using mean and standard deviation and qualitative variables using frequency and percentage. The Chi-square test, the t-test, and the Mann–Whitney U test were used for quantitative variable analysis. Logistic regression analysis was performed to assess the independent association of variables in predicting outcomes. The Kaplan–Meier method was also performed to check survival. A P value less than 0.05 was considered significant.

3. Results

This retrospective study included 344 patients diagnosed with COVID-19. The characteristics of patients are shown in Table 1. The average O2 saturation before and after the treatment was 84.80 ± 12.36 and 91.96 ± 5.82, respectively. Among patients, 58.7% were male and 41.3% were female. From the point of medical history, 43.6% had no comorbidities, while 20.6%, 9%, and 8.4% of the patients had diabetes, hypertension, and heart disease, respectively. Of all patients, 69.5% survived and were discharged from the hospital, while the rest (30.5%) died at the hospital (during hospitalization). 26.2% of patients were admitted to ICU, whereas 79.7% and 29.9% took immunosuppressive drugs and intubated, respectively. Regarding WBC level, at 67.7%, it was in the normal range, while at 27.3%, it was increased, and at 4.9%, it was decreased.

3.1. Pulmonary indicators

Based on the explanations given earlier in the method section, 2.6% of patients had no pulmonary involvement, and 9.6%, 16.9%, 19.8%, 25.9%, and 25.3% of patients had pulmonary involvement scores of 5, 10, 15, 20, and 25, respectively Also, 3.2% of patients had Pneumothorax, and 2.4% had cavitary lesions (Table 2).

3.2. Characteristics of cavitary lung lesions

Of all patients, 18 (2.4%) had cavitary lesions. The characteristics of cavitary lesions were as follows: the average number of lesions and the involved lobes were 1.33 ± 0.76 and 3.0 ± 1.41, respectively. The size and wall thickness of cavitary lesions were 28.83 ± 26.82 mm and 4.86 ± 3.3 mm, respectively.

Table 1. The characteristics of COVID-19 patients.

Variables		(Mean ± SD) (n = 344)	
Age (years)		60.20 ± 17.96	
Baseline O_2 saturation (%)		84.80 ± 12.36	
O_2 saturation after treatment (%)		91.96 ± 5.82	
Variables		N	(%)
Sex	Male	202	58.7
	Female	142	41.3
Comorbidities	No	150	43.6
	Diabetes	71	20.6
	Hypertension	31	9
	Heart disease	29	8.4
	Other	63	18.3
Survived	Yes	239	69.5
	No	105	30.5
ICU admission	Yes	90	26.2
	No	254	73.8
Immunosuppressive drugs consumption	Yes	274	79.7
	No	70	20.3
Intubation requirement	Yes	103	29.9
	No	241	70.1
WBC count	Normal	233	67.7
	Increased	94	27.3
	Decreased	17	4.9

Table 2. Pulmonary findings of COVID-19 patients on chest CT scan.

variables		N	(%)
Pulmonary involvement severity score	0	9	2.6
	1	33	9.6
	2	58	16.9
	3	68	19.8
	4	89	25.9
	5	87	25.3
Pneumothorax	Yes	11	3.2
	No	333	96.8
Cavitary lesion	Yes	18	2.4
	No	326	97.6

3.3. Assessment of the relation between clinical data and cavitary lung lesions

The mean oxygen saturation before and after treatment was significantly lower in patients with cavitary lesions (79.38 ± 10.14, 89.61 ± 5.60) than in patients without it (85.09 ± 12.43, 92.09 ± 5.83) ($p = 0.028$, $p = 0.003$). The percentage of males in both groups with (88.9 vs. 11.1%) and without (57.2 vs. 42.8%) cavitary lesions was significantly higher than females ($p = 0.005$). The percentage of patients who had cavitary lesions and survived was significantly lower than patients without lesions (44.4 vs 70.8%) ($p = 0.021$). Regarding the pulmonary involvement severity score, the results showed that the percentage of patients with pulmonary involvement greater than 20% was higher in the group with cavitary lesions ($p = 0.018$). On the other hand, there was no significant relationship between the two groups in terms of comorbidities, ICU admission, immunosuppressive drug consumption, intubation requirement, and WBC count variables ($p > 0.05$) (Table 3).

3.4. Evaluation of logistic regression and correlation of variables with cavitary lesions

In Table 4, the relationship between mortality, oxygen saturation, male gender, and severity of pulmonary involvement with the presence of cavitary lesions was examined. Analyses showed that in-hospital mortality, male gender, and severity of lung involvement were significantly associated with cavitary lesions.

3.5. Evaluation of survival analysis according to patients' clinical and radiologic characteristics

The Kaplan–Meier method was used to analyze survival. The results showed that patients with no comorbidities, no cavitary lesions, and less lung involvement had an increased chance of survival. In patients with cavitary lesions, those with fewer had an increased survival (Fig. 1).

4. Discussion

The current study evaluated the presence and characteristics of cavitary lesions on the chest CT scan of COVID-19 patients, and their relationship with clinical findings was studied. These

Table 3. Comparison of clinical data of COVID-19 patients with and without cavitary lesions.

Variables		With cavitary lesion		Without cavitary lesion		p-value
Baseline O_2 saturation		79.38 ± 10.14		85.09 ± 12.43		0.028
O_2 saturation after treatment		89.61 ± 5.60		92.09 ± 5.83		0.003
Variables		N	(%)	N	(%)	p-value
Sex	Male	16	88.9	186	57.2	0.005
	Female	2	11.1	139	42.8	
Comorbidities	No	5	27.8	145	44.6	0.293
	Diabetes	7	38.9	64	19.7	
	Hypertension	2	11.1	29	8.9	
	Heart disease	2	11.1	27	8.3	
	Other	2	11.1	60	18.5	
Survived	No	10	55.6	95	29.2	0.021
	Yes	8	44.4	230	70.8	
ICU admission	Yes	5	27.8	84	25.8	0.521
	No	13	72.2	241	74.2	
Immunosuppressive drugs consumption	Yes	15	83.3	258	79.4	0.481
	No	3	16.7	67	20.6	
Intubation requirement	Yes	7	38.9	96	29.5	0.275
	No	11	61.1	229	70.5	
WBC count	Normal	11	61.1	222	68.3	0.360
	Increased	7	38.9	87	26.5	
	Decreased	0	0	17	5.2	
Pneumothorax	Yes	0	0	11	3.4	0.548
	No	18	100	314	96.6	
Pulmonary involvement severity score	No	0	0	9	2.8	0.018
	<20	3	16.7	156	48	
	>20	15	83.2	160	49.2	

Table 4. Analysis of logistic regression and correlation of variables with the presence of cavitary lesions.

Cavitary lesion	P value	Std. Error	Odds Ratio	95% Confidence Interval	
				Lower	Upper
Mortality	0.024	0.49	3.026	1.15	7.9
O_2 saturation	0.377	1.06	0.377	1.15	7.9
Male gender	0.018	0.75	5.97	1.35	26.42
Pulmonary involvement severity	0.014	0.64	1.58	1.38	17.17

lesions have rarely been reported in patients with COVID-19.

Although the etiology of cavitation in COVID-19 pneumonia is obscure, regarding prior autopsy results, it may be due to diffuse alveolar damage, alveolar hemorrhage, and necrosis of parenchymal cells.[21,22]

Our results showed that oxygen saturation levels, before and after treatment, were higher in patients without cavitary lesions, and the difference was statistically significant ($p < 0.05$). However, logistic regression analysis showed that oxygen saturation level had no significant relationship with cavitary lesions.

In line with the results of our study, Zomout et al. demonstrated that patients with COVID-19 who had cavitary lesions had worse clinical conditions and needed aggressive treatment.[23] Kruse et al.'s study reported that patients with cavitary lesions on CT scans had more severe clinical symptoms.[24] Another study showed that COVID-19 patients with cavitary lesions needed oxygen therapy.[25]

The present study showed that survival status was higher in patients with no cavitary lesions than in patients with cavitary lesions, which was statistically significant ($p < 0.05$). In addition, regression analysis revealed that cavitary lesions can be related to the mortality rate. Also, survival analysis demonstrated that the presence and number of cavitary lesions, degree of lung involvement, and comorbidities were associated with survival rates.

In one study, it was demonstrated that the presence of cavitary lesions in patients may require aggressive treatments to improve their clinical symptoms.[26] In the study of Selvaraj et al., cavitary

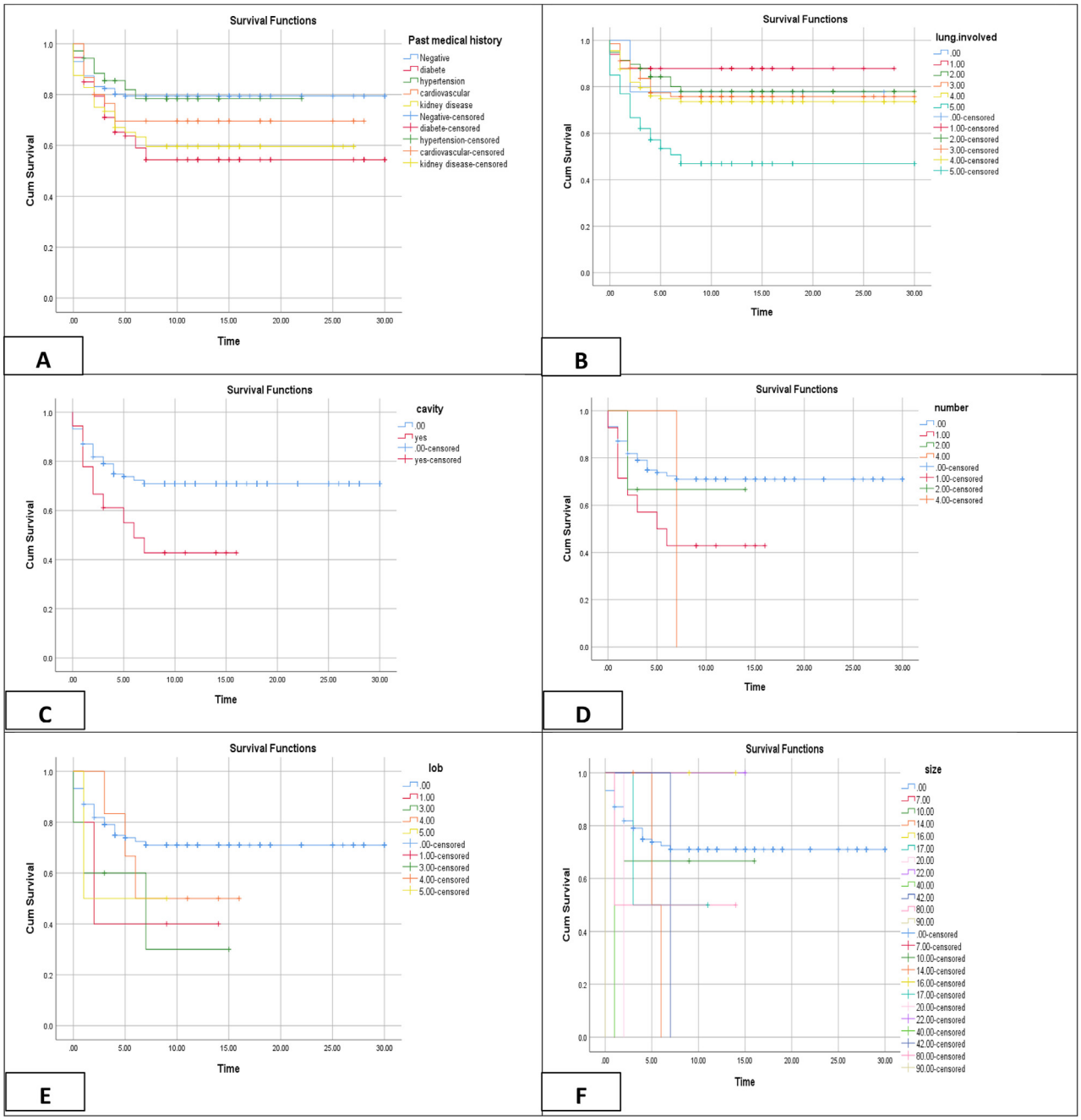

Fig. 1. The Kaplan–Meier plot to assess survival. A: past medical history, B: severity of lung involvement, C: the presence of a cavitary lesion, D: number of cavitary lesions, E: lobe containing cavitary lesion, F: the size of the cavitary lesion.

lesions were observed on the CT scan of a 52-year-old patient with COVID-19. The patient's symptoms improved following antibiotic consumption and oxygen therapy.[27] Another study showed that patients with cavitary lesions require monitoring and treatment to improve their clinical symptoms.[28] Also a study reported the presence of a cavitary lesion in a COVID-19 patient that disappeared with antiviral treatment.[29] Cavitary lesions are uncommon in COVID-19 patients that is concordant with our findings (prevalence of 2.4% in our study group).

Based on the current and previous studies, the presence of cavitary lesions can be related to the mortality of patients; therefore, it is necessary to adopt appropriate strategies for patients with cavitary lesions to increase survival. In the present study, there was no significant relationship between the length of hospitalization, intubation, hospitalization in ICU, and the consumption of

immunosuppressants in patients with and without cavitary lesions ($p > 0.05$).

Krues et al. conducted a study to evaluate the prevalence of cavitary lesions on the chest CT scan of patients with COVID-19. Cavitary lesions were observed on the CT scan of more than 50% of critically ill patients who were admitted to the ICU. In some patients, the size of these cavitary lesions decreased with patient treatment, while in some other patients, the size increased without the effect of drugs. The results showed that the presence of cavitary lesions in patients with COVID-19 can be associated with severe clinical symptoms; in addition, it can be accompanied by an increase in thrombosis and embolism, which aggravates the clinical process.[24] In another study, it was shown that patients with cavitary lesions were hospitalized for a longer period of time. In addition, the presence of cavitary lesions was associated with the progression of disease and lack of response to treatment. It was revealed that the presence of cavitary lesions can be associated with the severity and progression of the disease. Therefore, it can be concluded that the presence of cavitary lesions on CT scans of patients can be associated with an increase in mortality.[23]

5. Conclusion

The results suggest that the development of cavitary lesions can be related to mortality rate, severity of pulmonary involvement, and gender.

Data availability

Data availability is corresponding author responsibility.

Ethical approval

All the procedures performed on participants followed the ethical standards of the local ethics committee of Tehran University of Medical Science (IR. TUMS.SINA HOSPITAL.REC.1401.040), as well as the 1964 Helsinki Declaration.

Consent for publication

Not applicable.

Funding

None.

Conflict of interest

The authors declare that they have no conflict of interest.

References

1. Yang L, Liu S, Liu J, et al. COVID-19: immunopathogenesis and Immunotherapeutics. *Signal Transduct Targeted Ther*. 2020; 5(1):128.
2. Shayan S, Jamaran S, Askandar RH, et al. The SARS-Cov-2 Proliferation blocked by a novel and potent main protease inhibitor via computer-aided drug design. *Iran J Pharm Res (IJPR): IJPR*. 2021;20(3):399.
3. Nokhostin F, Dargahi MalAmir M, Tutunchi S, Rezaeeyan H. Evaluation of prognostic/diagnostic value of Hematological markers in the detection of inflammation in coronavirus disease: a review study. *J Adv Med Biomed Res*. 2020;28(128): 171–174.
4. Yuki K, Fujiogi M, Koutsogiannaki S. COVID-19 pathophysiology: a review. *Clin Immunol*. 2020;215:108427.
5. Iba T, Levy JH, Connors JM, Warkentin TE, Thachil J, Levi M. The unique characteristics of COVID-19 coagulopathy. *Crit Care*. 2020;24(1):1–8.
6. Fattahi F, Farnia MR, Rezaei B, et al. COVID-19 patients' lung involvement severity as a predictor of kidney dysfunction and coagulopathy disorders. *J Renal Endocrinol*. 2023;9(1):e25096-e.
7. Rezaeeyan H, Arabfard M, Rasouli HR, Shahriary A, Gh BFNM. Evaluation of common protein biomarkers involved in the pathogenesis of respiratory diseases with proteomic methods: a systematic review. *Immunity, Inflammation and Disease*. 2023;11(11):e1090.
8. Ji T, Liu Z, Wang G, et al. Detection of COVID-19: a review of the current literature and future perspectives. *Biosens Bioelectron*. 2020;166:112455.
9. Tahamtan A, Ardebili A. Real-time RT-PCR in COVID-19 detection: issues affecting the results. *Expert Rev Mol Diagn*. 2020;20(5):453–454.
10. Aghazade N, Arjmand A, Arabsorkhi M, Rahmani V. What special precautions are required while anesthetizing COVID-19 patients in the operation room? *Journal of Preventive Epidemiology*. 2024;9(1).
11. Amin A, Maleki S, Moonesan MR. Nirmatrelvir-ritonavir efficacy and safety in high-risk COVID-19 patients: a review of recent retrospective cohort studies—nephrology point of view. *J Ren Inj Prev*. 2024:e32257.
12. Canan A, Batra K, Saboo SS, Landay M, Kandathil A. Radiological approach to cavitary lung lesions. *Postgrad Med*. 2021;97(1150):521–531.
13. Zeinali-Rafsanjani B, Alavi A, Lotfi M, Haseli S, Saeedi-Moghadam M, Moradpour M. Is it necessary to define new diagnostic reference levels during pandemics like the Covid 19-? *Radiat Phys Chem*. 2023;205:110739.
14. Salahshour F, Mehrabinejad M-M, Nassiri Toosi M, et al. Clinical and chest CT features as a predictive tool for COVID-19 clinical progress: introducing a novel semi-quantitative scoring system. *Eur Radiol*. 2021;31:5178–5188.
15. Norouzi M, Hashemi M, Pouri Z. The question of global society in post-corona time: towards a paradigm shift. *Intern J Commun Well-Being*. 2021;4:339–343.
16. Liang T, Liu Z, Wu CC, et al. Evolution of CT findings in patients with mild COVID-19 pneumonia. *Eur Radiol*. 2020;30: 4865–4873.
17. Afrazi A, Garcia-Rodriguez S, Maloney JD, Morgan CT. Cavitary lung lesions and pneumothorax in a healthy patient with active coronavirus-19 (COVID-19) viral pneumonia. *Interact Cardiovasc Thorac Surg*. 2021;32(1):150–152.
18. Salesi M, Sedarat M. Clinical signs, symptoms, and severity of COVID-19 in patients with rheumatic diseases during the COVID-19 epidemic. *Immunopathologia Persa*. 2023;10(1): e40568-e.
19. Asadbeygi A, Lee S, Kovalchin J, Hatoum H. Effect of beta blockers on the hemodynamics and thrombotic risk of coronary artery aneurysms in Kawasaki disease. *Journal of Cardiovascular Translational Research*. 2023;16(4):852–861.
20. Li K, Wu J, Wu F, et al. The clinical and chest CT features associated with severe and critical COVID-19 pneumonia. *Invest Radiol*. 2020;55(6):327–331.

21. Menter T, Haslbauer JD, Nienhold R, et al. Post-Mortem examination of COVID19 patients reveals diffuse alveolar damage with severe capillary congestion and variegated findings of lungs and other organs suggesting vascular dysfunction. *Histopathology*. 2020;77(2):198−209.
22. Yao XH, Li TY, He ZC, et al. A pathological report of three COVID-19 cases by minimal invasive autopsies. *Zhonghua Bing Li Xue Za Zhi*. 2020;49:411−417.
23. Zoumot Z, Bonilla M-F, Wahla AS, et al. Pulmonary cavitation: an under-recognized late complication of severe COVID-19 lung disease. *BMC Pulm Med*. 2021;21:1−8.
24. Kruse JM, Zickler D, Lüdemann WM, et al. Evidence for a thromboembolic pathogenesis of lung cavitations in severely ill COVID-19 patients. *Sci Rep*. 2021;11(1):16039.
25. Vural A, Kahraman AN. Pulmonary embolism and giant cavitary lesion developing after COVID-19 pneumonia. *HCA Healthcare Journal of Medicine*. 2020;1:11.
26. Garg M, Prabhakar N, Muthu V, et al. CT findings of COVID-19−associated pulmonary mucormycosis: a case series and literature review. *Radiology*. 2022;302(1):214−217.
27. Selvaraj V, Dapaah-Afriyie K. Lung cavitation due to COVID-19 pneumonia. *BMJ Case Rep*. 2020;13(7):e237245.
28. Muheim M, Weber FJ, Muggensturm P, Seiler E. Case report: an unusual course of disease in two patients with COVID-19: pulmonary cavitation. *BMJ Case Rep*. 2020; 13(9).
29. Xu Z, Pan A, Zhou H. Rare CT feature in a COVID-19 patient: cavitation. *Diagn Interventional Radiol*. 2020;26(4):380.